

Anodyne therapy for recalcitrant diabetic foot ulcers: a report of four cases

A Nather, YE Sim, LLJ Chew, SH Neo

Department of Orthopaedic Surgery, Yong Loo Lin School of Medicine, National University of Singapore, Singapore

ABSTRACT

Four patients with diabetic foot ulcers that failed to heal after one month of treatment underwent anodyne therapy. Each therapy session lasted half an hour and was conducted 3 times a week for patients at home or daily for patients in hospital, for one to 2 months. The wound sizes and depths were graded according to the Wagner classification. Pictures were taken to evaluate the effects of anodyne therapy. All 4 patients had good healing of their foot ulcers. Anodyne therapy augments the effects of conservative treatment. Proper wound care and appropriate antibiotic coverage remain the basis of treatment.

Key words: *diabetic angiopathies; diabetic foot; diabetes mellitus; wound healing*

INTRODUCTION

Diabetes mellitus involved 8.2% of the Singaporeans aged 18 to 69 in 2004.¹ Foot ulcers take a longer time to heal in diabetics because of pathogenic abnormalities: intrinsic defects in blood supply, angiogenesis, and extrinsic factors of infection and trauma causing delayed healing.² Diabetic patients lack bioavailable nitric oxide (NO) resulting in poor blood supply in the foot.^{3,4} Monochromatic infrared energy or anodyne therapy has been used to promote healing in diabetic foot ulcers, because it increases NO concentration in the bloodstream and dilates blood vessels in the foot.⁵

CASE REPORTS

Four patients with ulcers that failed to heal after one month of treatment underwent anodyne therapy. Their

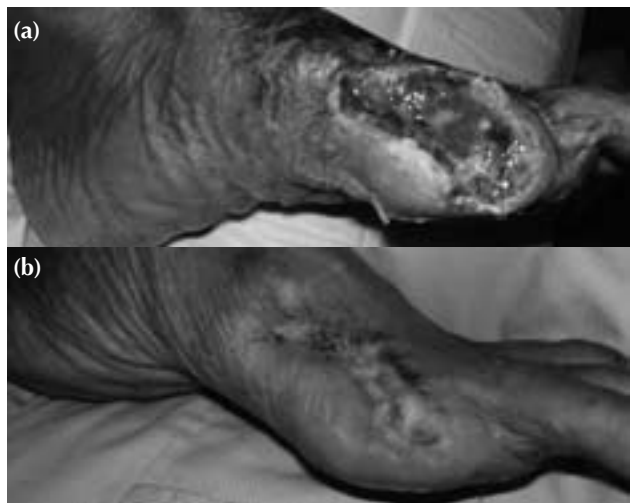

Figure 1 Patient 1: (a) grade-2 surgical ulcer measuring 5.5x3.5 cm, (b) completely healed ulcer at day 43.

wounds were covered with clear plastic (Tagaderm), and anodyne therapy system pads were placed over the plastic to prevent contamination, and on the lateral and medial aspects of the ipsilateral calf. Each therapy session lasted half an hour and was conducted 3 times a week (Monday, Wednesday, Friday) for patients at home or daily for patients in hospital, for one to 2 months. Wounds were cleaned and dressed after each session to minimise disturbances to the wound. No adverse symptoms or events were noted in any patients during therapy. Patients were assessed for peripheral neuropathies, pedal pulses, and wound size before and after therapy. Pictures were taken at each session to evaluate the effects of anodyne therapy on wound healing. Wound sizes and depths were graded according to the Wagner classification.⁶

Case 1

In February 2006, a 54-year-old woman with a 2-year history of diabetes presented with gangrene of the left big toe. She had no neuropathy, and both dorsalis pedis and posterior tibialis pulses were palpable. She underwent ray amputation and wound debridement. Anodyne therapy was performed for the grade-2 surgical ulcer measuring 5.5x3.5 cm thrice weekly at her home. After each session, the wound was cleaned with 5% chlorhexidine solution and dressed with tulle gras. The wound healed 43 days later (Fig. 1).

Case 2

In September 2005, a 73-year-old man with a 20-year

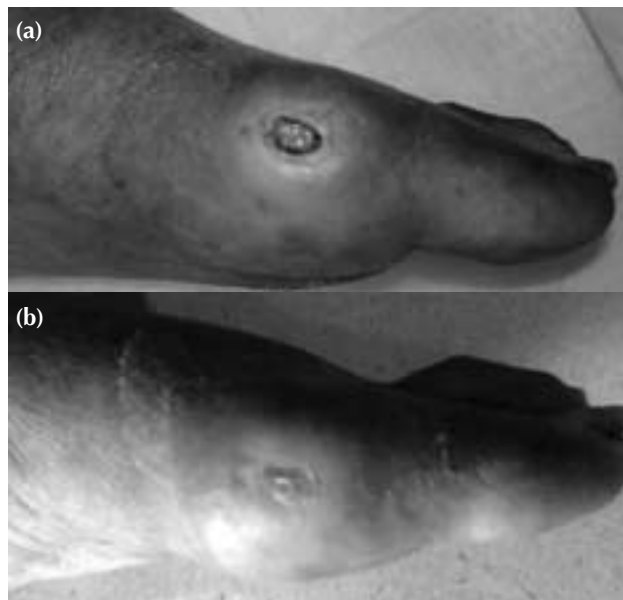


Figure 2 Patient 2: (a) grade-2 ulcer (capsule of metatarsophalangeal joint exposed) measuring 1.5 cm in diameter, (b) completely healed ulcer at day 34.

history of diabetes sustained a fracture of his left fourth and fifth metatarsals after a fall. He was treated with a below-knee plaster cast. A small ulcer over the medial aspect of his left big toe was detected 2 weeks later. Both dorsalis pedis and posterior tibialis pulses were not palpable, and he had bilateral glove and stocking neuropathy up to his ankle. The ulcer was grade 2 (the metatarsophalangeal joint capsule was exposed), measuring 1.5 cm in diameter and was treated with dressings for 5 months without success. He underwent anodyne therapy thrice weekly at his home. After each session, the wound was cleaned with 5% chlorhexidine solution and dressed with polymem. The ulcer healed 34 days later (Fig. 2).

Case 3

In February 2006, a 68-year-old man with a 4-year history of diabetes presented with gangrene of the left fifth toe. Both dorsalis pedis and posterior tibialis pulses were palpable. He underwent ray amputation, followed by anodyne therapy thrice weekly at his home. The surgical ulcer was grade 2 in depth and measured 5x3.5 cm. After each session, the wound was cleaned with 5% chlorhexidine solution and dressed with duoderm gel. 45 days later, the wound shrank and measured 3x2 cm. Anodyne therapy was stopped and daily duoderm gel dressings continued. The wound healed completely after a further 21 days (Fig. 3).

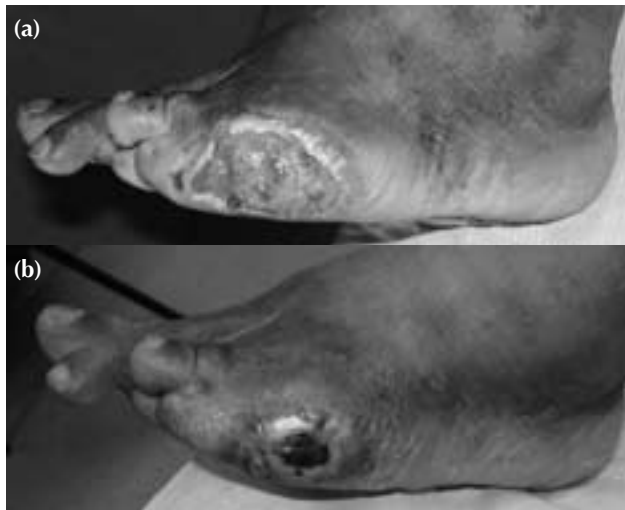


Figure 3 Patient 3: (a) grade-2 ulcer measuring 5x3.5 cm, (b) shrunken ulcer with clean granulating bed measuring 3x2 cm at day 45.

Case 4

In January 2006, an 85-year-old woman with a 15-year history of diabetes presented with 2 superficial ulcers over the dorsum of her left foot. Both dorsalis pedis and posterior tibialis pulses were palpable, and the patient had no neuropathy. She underwent debridement and anodyne therapy. The ulcer on the medial side measured 2.5x2 cm and that on the lateral side near the lateral malleolus measured 6x4.5 cm. Both ulcers were grade 1. After each session, her wound was cleaned with 5% chlorhexidine solution and dressed with tulle gras. Both wounds healed 52 days later (Fig. 4).

DISCUSSION

NO is an endogenous vasodilator produced by endothelial NO synthetase during the oxidation of L-arginine to L-citrulline and NO.³ Patients with diabetes often lack bioavailable NO due to reduced production of NO by NO synthetase and inactivation of NO by reactive oxygen species produced by glycated proteins or from vascular endothelium.^{3,4} A small proportion of NO released into the vascular lumen is also transported in blood in the form of S-Nitrosothiol attached to haemoglobin.^{4,7} In diabetic patients with elevated levels of glycated red blood cells, an increase in NO binding to red blood cells

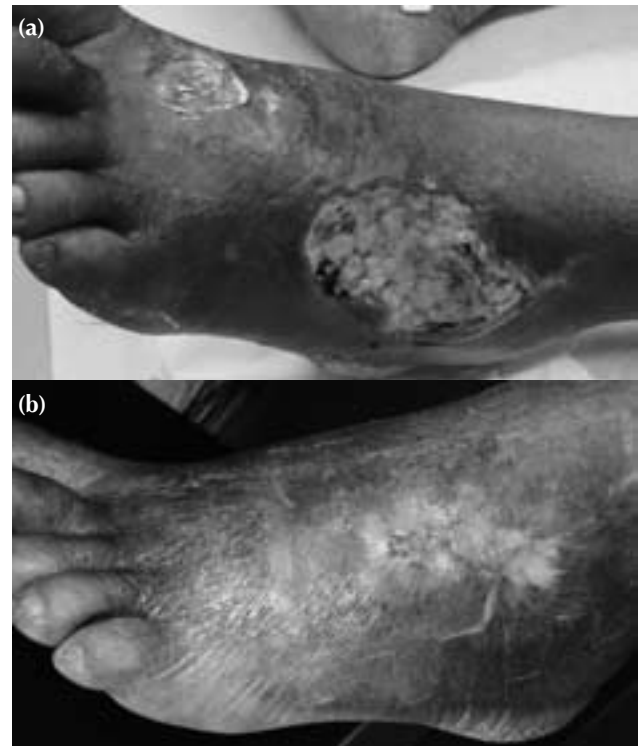

Figure 4 Patient 4: (a) grade-1 ulcers measuring 2.5x2 cm and 6x4.5 cm, (b) both ulcers healed completely at day 52.

decreases delivery of vasoactive NO to hypoxic tissues.⁴

Monochromatic infrared energy (MIRE) treatment may increase local and systemic levels of NO in diabetic patients. NO has been found to be liberated from haemoglobin on exposure to various wavelengths of energy.⁸ Plasma NO in non-diabetic subjects increased after MIRE application to the skin for 30 minutes.⁵ The exact mechanism is still unknown. Far infrared therapy (FIR) in a rat model stimulated skin blood flow, which was maintained for a period afterward. This increase in circulation was mainly due to an increase in NO synthetase activity, rather than a hyperthermic effect, as this post-FIR enhancement of skin blood flow can be inhibited by NG-nitro-L-arginine methyl ester, an inhibitor of NO synthetase activity.^{9,10} The foot circulation increased in diabetic patients with microangiopathy after treatment with visible red monochromatic energy, and this was sustained even after the treatment discontinued.¹¹ Hence, anodyne therapy is useful for patients with diabetic foot ulcers and poor blood supply; it has successfully healed wounds that have become stagnant or deteriorated.^{5,12,13}

Our study lacks controls not receiving anodyne therapy nor wound dressings to compare with our subjects. Anodyne therapy is labour intensive. A thrice-weekly home visit is difficult to implement and limits the number of treated patients. A viable alternative is to provide patients with home therapy units. The patients could first be educated about its use and then perform the therapy sessions themselves. This is already practised in the United States where patients may rent-to-own an anodyne therapy system. Another option would be to establish anodyne therapy centres in local hospitals and polyclinics similar to those in the United States, where patients receive such therapy regularly.

CONCLUSION

Anodyne therapy enhances the healing of ischaemic foot ulcers in diabetic patients. Proper wound care and use of appropriate antibiotics remain the basis of treatment, as anodyne therapy augments, but is not a substitute for, conservative treatment.

ACKNOWLEDGEMENT

We thank All Eight Singapore Ptd Ltd for lending the anodyne therapy units and Mr Lee Poh Seng for his help and advice.

REFERENCES

1. Epidemiology and Disease Control Division of the Ministry of Health, Singapore. National Health Survey 2004.
2. Falanga V. Wound healing and its impairment in the diabetic foot. *Lancet* 2005;366:1736–43.
3. Forstermann U, Munzel T. Endothelial nitric oxide synthase in vascular disease: from marvel to menace. *Circulation* 2006;113:1708–14.
4. James PE, Lang D, Tufnell-Barret T, Milsom AB, Frenneaux MP. Vasorelaxation by red blood cells and impairment in diabetes: reduced nitric oxide and oxygen delivery by glycated hemoglobin. *Circ Res* 2004;94:976–83.
5. Horwitz LR, Burke TJ, Carnegie D. Augmentation of wound healing using monochromatic infrared energy. Exploration of a new technology for wound management. *Adv Wound Care* 1999;12:35–40.
6. Wagner FW Jr. The diabetic foot. *Orthopedics* 1987;10:163–72.
7. Allen BW, Piantadosi CA. How do red blood cells cause hypoxic vasodilation? The SNO-hemoglobin paradigm. *Am J Physiol Heart Circ Physiol* 2006;291:H1507–12.
8. Matsunaga K, Furchgott RF. Interactions of light and sodium nitrite in producing relaxation of rabbit aorta. *J Pharmacol Exp Ther* 1989;248:687–95.
9. Yu SY, Chiu JH, Yang SD, Hsu YC, Lui WY, Wu CW. Biological effect of far-infrared therapy on increasing skin microcirculation in rats. *Photodermatol Photoimmunol Photomed* 2006;22:78–86.
10. Akasaki Y, Miyata M, Eto H, Shirasawa T, Hamada N, Ikeda Y, et al. Repeated thermal therapy up-regulates endothelial nitric oxide synthase and augments angiogenesis in a mouse model of hindlimb ischemia. *Circ J* 2006;70:463–70.
11. Schindl A, Schindl M, Schon H, Knobler R, Havelec L, Schindl L. Low-intensity laser irradiation improves skin circulation in patients with diabetic microangiopathy. *Diabetes Care* 1998;21:580–4.
12. C Fife. Anodyne therapy in painful hypoxic wounds. Reversal of gangrene. Proceedings of the 17th Annual Clinical Symposium on Advances in Skin and Wound Care; 2002 Sep 21-24; Dallas, US.
13. Poster, Anders, Walker, Fife, Bachmann. The use of monochromatic infrared energy in treatment of ischemic pain and foot ulcerations. Proceedings of the 17th Annual Clinical Symposium on Advances in Skin and Wound Care; 2002 Sep 21-24; Dallas, US.